



ORIGINAL RESEARCH

Medicine Science 2017;6(1):1-4

When and how should leeches be applied in cases of venous congestion?

Cengiz Aldemir, Fatih Duygun

Antalya Education and Research Hospital, Orthopaedics and Traumatology Department, Antalya, Turkey

Received 31 May 2016; Accepted 23 June 2016

Available online 30.06.2016 with doi: 10.5455/medscience.2016.05.8498

Abstract

Aim of this study is to discuss the results of cases where leeches were applied to prevent the development of venous congestion following replantation and flap surgery. Methods Leeches were applied to a total of 31 patients with appropriate and sufficient follow-up in the Orthopaedics and Traumatology Clinics of Antalya State Hospital and Antalya Training and Research Hospital between 1997 and 2015. The patients comprised 20 cases of replantation and 11 cases of crush syndrome. The rates of necrosis were examined in these patients following the application of leeches. Results Following the application of leeches, necrosis was determined in 5 of the 20 adult replantation or revascularisation cases with venous congestion and in 6 of the 11 cases of crush injury. No serious allergic reaction was observed in any case following leech application. Conclusion In patients with replantation or crush injuries who cannot be treated by conventional methods, the application of leeches is an effective method in the treatment of venous congestion.

Keywords: Replantation, crush, leeches, venous congestion

Introduction

Venous congestion is a not uncommon event seen following crush injuries or microvascular surgery such as flap or replantation [1]. In a flap or replantation developing venous congestion, the tissue is tight, the colour is blue-purple, capillary filling is more rapid than normal and the skin bleeds more quickly. Venous congestion must be diagnosed early and venous drainage must be provided without any loss of time. The application of leeches is a treatment option for venous congestion which occurs after replantation and free tissue transfers [2].

For venous drainage;

- 1- New vein anastomosis,
- 2- Excision of the nail bed of the replanted finger and the application of heparin sponge,
- 3- Massage of the replanted finger and administration of systemic heparin,
- 4- Incision to the finger tip,
- 5- Leech application can be made.

The aim of this study was to determine the timing and efficacy of leech application for venous congestion which has developed.

Material and Method

Leeches were applied to a total of 31 selected patients with sufficient follow-up in the Orthopaedics and Traumatology Clinic of Antalya Training and Research Hospital and Antalya State Hospital in the period 1997-2015. Of the total patients, 20 were applied with replantation and revascularisation and 11 presented following crush injuries. The patients were 27 males and 4 females with a mean age of 32 years (range, 17-50 years). (Table 1).

	Replantation	Crush Injury
Patient	20	11
Gender (F:M)	01:19	03:08
Necrosis	5	6

Table 1. Patient Distribution

The stages of application:

- 1- The finger end is cleaned with distilled water.
- 2- The area around the application is covered with gauze.
- 3- The pulp is pierced with a sterile needle for bleeding to occur.
- 4- The leech is held in a gloved hand and attached to the bleeding area.

Depending on the status of the venous congestion area, leeches were applied 3-5 times per day for a period of 4-7 days. During the application, within 10-20 minutes of attachment, the leeches spontaneously fell off. Depending on the frequency of the application, haemogram follow-up

*Corresponding Author: Cengiz Aldemir, Antalya Education and Research Hospital, Orthopaedics and Traumatology Department
E-mail: cengizaldemir@yahoo.com

was applied 2-3 times per day. All the patients were administered with prophylactic antibiotics of 3rd generation cephalosporin and fluoroquinolone group for 7-10 days and no additional antibiotics were given. The leeches used had been locally obtained and bottled from the wetlands and river banks in Antalya.

Results

The 20 patients applied with replantation and revascularisation in our clinic and in whom venous congestion then developed, presented directly at our clinic without having consulted any other healthcare institution. The time from injury to admittance for surgery of these 20 patients was mean 3.5 hours (range, 1-6 hours). Of the 11 patients with crush injuries, 6 were treated as outpatients for follow-up with a hand brace by external centres. These patients presented at our clinic at 1-3 days post-trauma. On presentation at our clinic, the finger ends of these patients were immediately pierced and in 4 patients, there was minimal serohaemorrhagic or serous fluid rather than blood and in 2 patients there was no bleeding or fluid discharge. The other 5 patients had presented at the Emergency Department and were immediately admitted to hospital for treatment.



Figure 1. A replantation case where venous congestion has developed. Leeches in a bottle

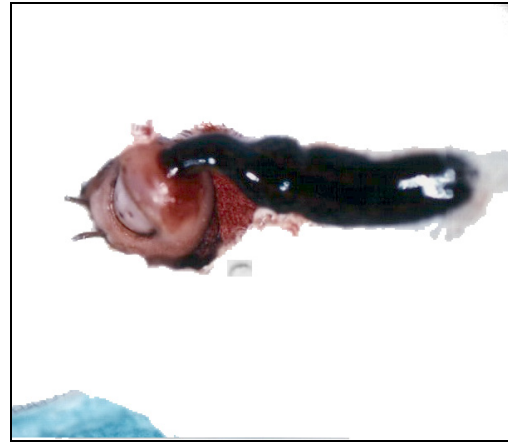


Figure 2. Leech application




Figure 3. After Leech application

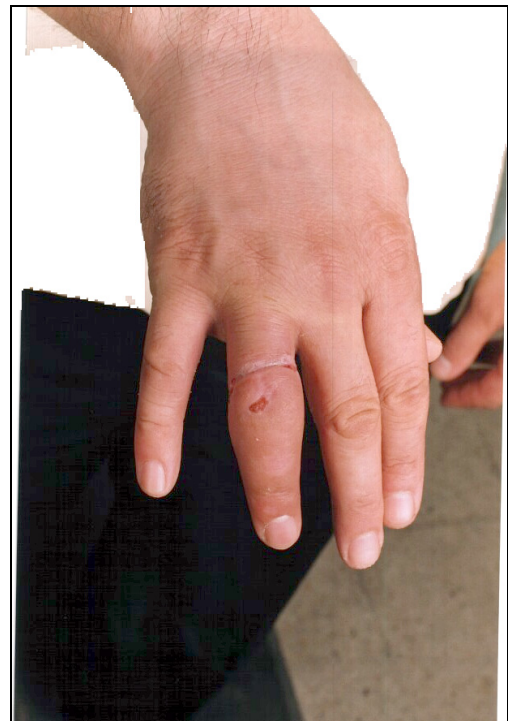

Figure 4. Image of the same case 8 weeks after leech treatment

Discussion

Venous congestion is a problem encountered as a result of microsurgery applied to patients and following crush injuries. The application of leeches (hirudotherapy) is an alternative treatment method to resolve this problem. The success of this application depends not only on the collaboration of the doctor, nurse and patient but also that it is not delayed and is applied for an appropriate period. Leeches produced by companies in the UK and USA cost £8 (GBP -sterling) each. The leeches used in the current study were gathered from the wetlands and rivers of the local Antalya region and were obtained at a cost of 80 kuruş each (approximately 0.25 USD). Leech therapy is generally used when the venous blood flow is insufficient and cannot meet the arterial flow. It can be used to achieve physiological venous drainage until angiogenesis occurs in free tissue transfers and finger replantations [4]. Applications in literature have been reported as mean 2-6 days [4] and in the current study, the leeches were applied for 4-7 days. Contraindications for hirudotherapy are arterial insufficiency, haemorrhage, haemorrhagic malignancies, anaemia, hypotension and sepsis [4]. There were no contraindications in any of the current study patients. The treatment is not recommended for pregnant or breast-feeding patients or those with an unstable medical condition. Leech therapy is generally applied when conventional treatment modalities, such as elevation, warming, aspirin, local heparin and vasodilators, have been applied and found to be insufficient. In the current study, these agents and treatment protocols were applied to all the patients and as an insufficient response was obtained, the leech treatment was applied. Microcirculatory thrombosis causes venous obstruction. Therefore, until neovascularisation occurs, temporary venous drainage can be provided with the leech treatment [5]. Antibiotic prophylaxis in leech treatment is for aeromonas bacteria which are symbiotic in the leech, and it must be administered before starting the leech treatment [6-7].

Aeromonas are sensitive to 2nd and 3rd generation cephalosporin, fluoroquinolone, tetracycline, TMP-sulfamethoxazole and aminoglycoside [8-10]. Chepeha et al administered antibiotic prophylaxis twice during leech application and continued it for 2 weeks after the treatment. In the Iowa head and neck protocol, levofloxacin is recommended and that it is continued for 24 hours after the completion of leech treatment. In the current study, 3rd generation cephalosporin and fluoroquinolone were used and no infection developed in any patient. In literature, similar results have been obtained with the use of *hirudo verbana* and *hirudo michaelseni* in addition to *hirudo medicinalis* in some cases [11]. Although the measurement of blood values has been recommended as once every 4 hours in literature, it can vary according to the frequency of the leech application [12]. In the current study, blood values were examined 2-3 times per day. In 3 patients

when haemoglobin fell to <8 gr/dl, transfusion was applied. Mumcuoğlu et al reported that of 9 cases of replantation and 6 of revascularisation, 10 (67%) fingers were saved with leech treatment.

Of the total 31 adult patients who were applied with leeches, necrosis developed in 6 of the 11 crush injury patients and in 5 of the 20 replantation and revascularisation patients and those fingers were lost. In 6 patients, when the pulp was pierced, there was minimal serohaemorrhagic or serous fluid in 4 patients and no fluid in 2 patients. In these patients, the leech immediately left the pierced area. The success rate of the current study was 75% in the replantation and revascularisation cases and 45.45% in the crush injury cases. Although reactions such as mild localised itching, pain, subfebrile fever, and localised lymphadenitis have been reported in literature, no reactions developed in any patient of the current study.

Conclusion

The application of leeches plays an effective role in the eradication of venous congestion but the decision to apply this treatment must not be delayed and there must be a state of bleeding in the pierced finger pulp. During the application of leech therapy, the patient must be closely monitored by the doctor and nurse for allergic reactions, signs of infection and the congestion status. In addition to monitoring of the vital signs of the patient, blood values should be monitored at least 2-3 times per day in parallel with the frequency of the leech applications and when necessary, transfusions must be made. Prophylactic antibiotics must certainly be administered to the patient.

References

- 1- Yıldız M, Karagüzel A. Application of leeches in Microsurgery. J Med Science. 1993;19(4):419-22.
- 2- Wells MD, Manktelow RT, Boyd JB, Bowen VB. The medical leech: An old treatment revisited. Microsurgery. 1993;14:183-6.
- 3- Biofarm Leeches. Product information.U.K. 1994.
- 4- Hartrampf CR Jr, Drazan L, Noel RT. A mechanical leech for transverse rectus abdominis musculocutaneous flaps. Ann Plast Surg. 1993;31(2):103-5.
- 5- Vural E, Key JM. Complications, salvage, and enhancement of local flaps in facial reconstruction. Otolaryngol Clin North Am. 2001;34(4):739-51.
- 6- Mumcuoğlu K, Pidhorz C, Cohen A, Ofek, Lipton H, The use of the medicinal leech, *Hirudo medicinalis*, in the reconstructive plastic surgery. The Internet J Plast Surg. 2006;4(2):1-9.
- 7- Mumcuoğlu KY, Huberman L, Cohen R, Temper V, Adler A, Galun R, Block C. Elimination of symbiotic *Aeromonas* spp. from the intestinal tract of the medicinal leech, *Hirudo medicinalis*, using ciprofloxacin feeding. Clin Microbiol Infect. 2010;16(6):563-7.
- 8- Nguyen MQ, Crosby MA, Skoracki RJ, Hanasono MM. Outcomes of flap salvage with medicinal leech therapy. Microsurgery. 2012;32(5):351-7.

- 9- Pereira JA, Greig JR, Liddy H, Ion L, Moss ALH, Leech-borne Serratia marcescens infection following complex hand injury. Br J Plast Surg. 1998;51(8):640-1.
- 10- Schnabl SM. Comment on Riede F, Koenen W, Goerd S, Ehmke H, Faulhaber J. Medicinal leeches for the treatment of venous congestion and hematoma after plastic reconstructive surgery in J Dtsch Dermatol Ges 2010;11:881-9. J Dtsch Dermatol Ges. 2011;9(6):490-1.
- 11- Whitaker IS, Oboumarzouk O, Rozen WM, Naderi N, Balasubramanian SP, Azzopardi EA, Kon M. The efficacy of medicinal leeches in plastic and reconstructive surgery: a systematic review of 277 reported clinical cases. Microsurgery. 2012;32(3):240-50.
- 12- Chepeha DB, Nussenbaum B, Bradford CR, Teknos TN. Leech therapy for patients with surgically unsalvageable venous obstruction after revascularized free tissue transfer. Arch Otolaryngol Head Neck Surg. 2002;128(8):960-5.