



# SALVAGE OF NEAR TOTAL TONGUE AMPUTATION WITH HIRUDOTHERAPY

Amir H. Ajar, MD‡; Benoit J. Gosselin, MD, FRCSC†  
University of Vermont College of Medicine‡, Dartmouth Medical School†



## ABSTRACT

Medicinal leeches are currently used in contemporary medicine as a useful adjunct for the reconstructive surgeon: providing relief of venous congestion in pedicled or free flaps. They have also been used for replantation surgery where arterial input can be established but not venous drainage. Their use has been reported in the treatment of scalp avulsions, periorbital hematomas, and breast surgery, among others.

We report the use of hirudotherapy in the treatment of an accidental near-total mobile tongue avulsion in a 14 year old male. Despite adequate initial primary surgical repair, the mobile tongue developed severe post-operative venocongestion by post-repair day two. Aggressive management with medicinal leeches allowed the salvage of the patient's tongue and the recovery of both speech and swallowing.

Keywords: Hirudotherapy, Leech Therapy, Tongue Avulsion, Wound Repair

## CASE REPORT

A healthy 15 year old male is seen after sustaining a traumatic through and through cheek (oral commissure) injury and near-total avulsion of two-thirds of the mobile tongue sustained in a skiing accident (Figure 1). He was initially stabilized, nasotracheally intubated and a primary multilayer repair of the tongue was accomplished. The patient received intravenous steroids and antibiotics. He developed severe post-operative vasocongestion and early signs of necrosis on post-repair day two (Figure 2). Prompt hirudotherapy was initiated on post-repair day three, and continued four times a day for ten days (Figure 3). At that point, his nasotracheal airway was converted to a formal tracheostomy; and the patient remained sedated throughout his course of hirudotherapy. Intravenous steroids were weaned and the patient maintained on intravenous quinolone prophylaxis per DHMC's hirudotherapy protocol. Careful daily hemogram and coagulation parameter monitoring were assured. The tongue viability was noted to slowly and steadily improve during therapy, with only minimal sloughing at the distal tip requiring local debridement at the bedside (Figure 4). Revision of the primary closure was required in the operating theater on post-repair day 12. The patient was then slowly weaned from sedation; and once awake and tolerating tracheostomy collar, decannulated without event.

The patient was discharged to a rehabilitation facility and followed as an outpatient. There were no neurologic sequelae from his prolonged sedation. A late follow-up at six months revealed an intact, mobile, sensate tongue (Figure 5) with intelligible speech and full range of PO intake without swallowing deficit.

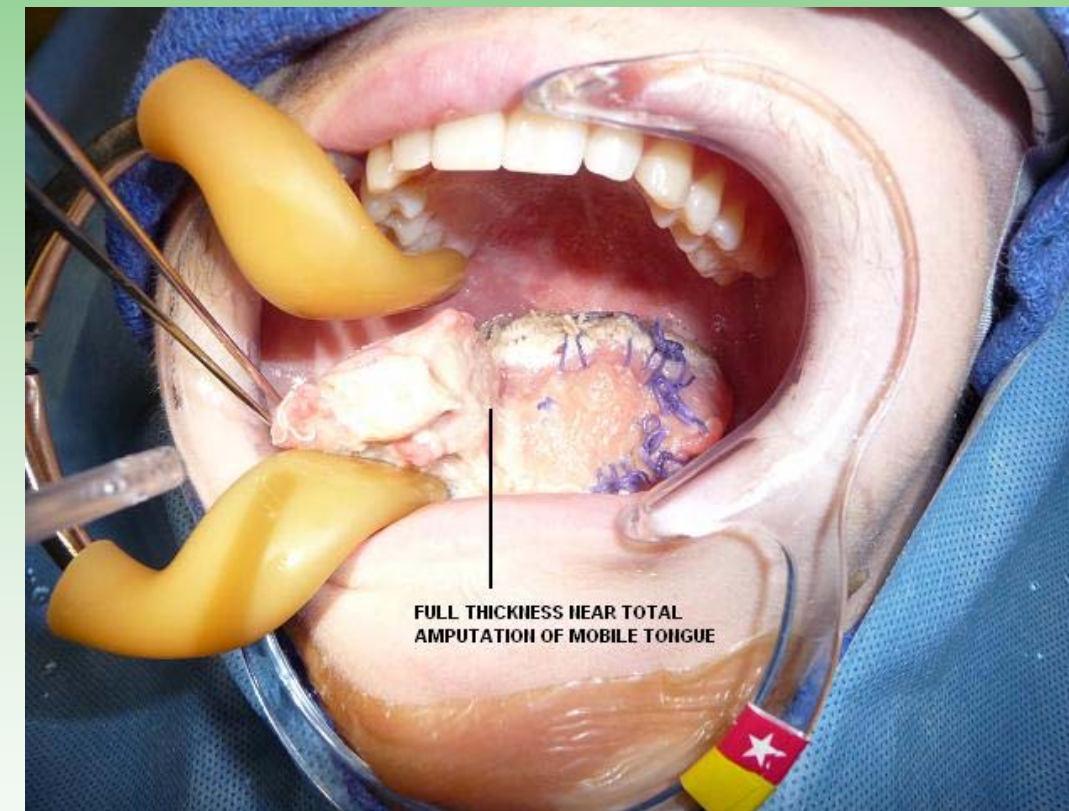


Figure 1: Initial Injury

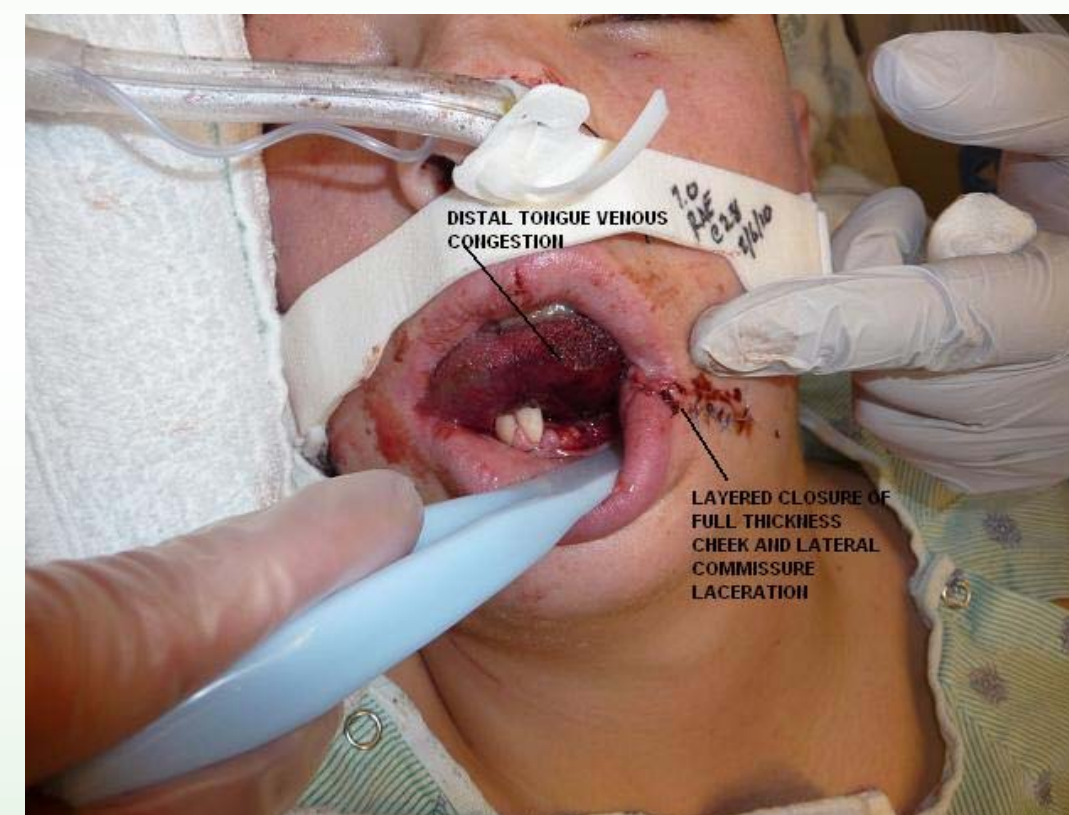

Figure 2: Venous Congestion following primary repair

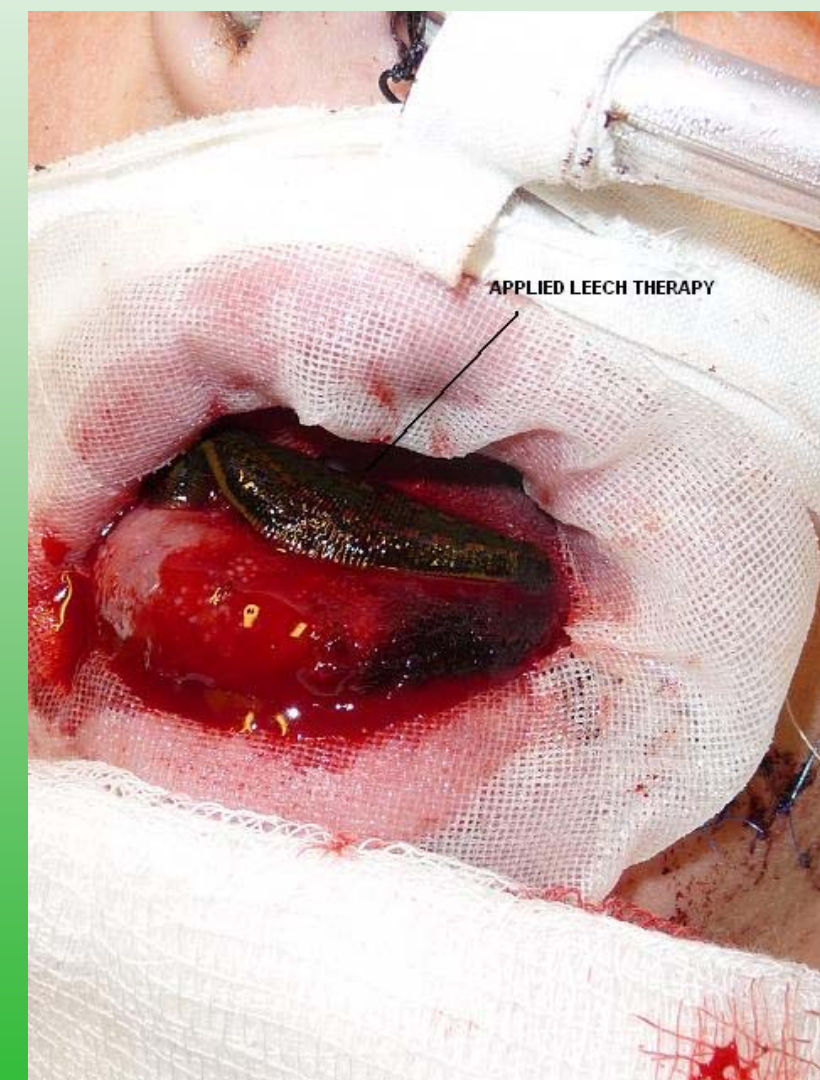

Figure 3: Application of Leeches

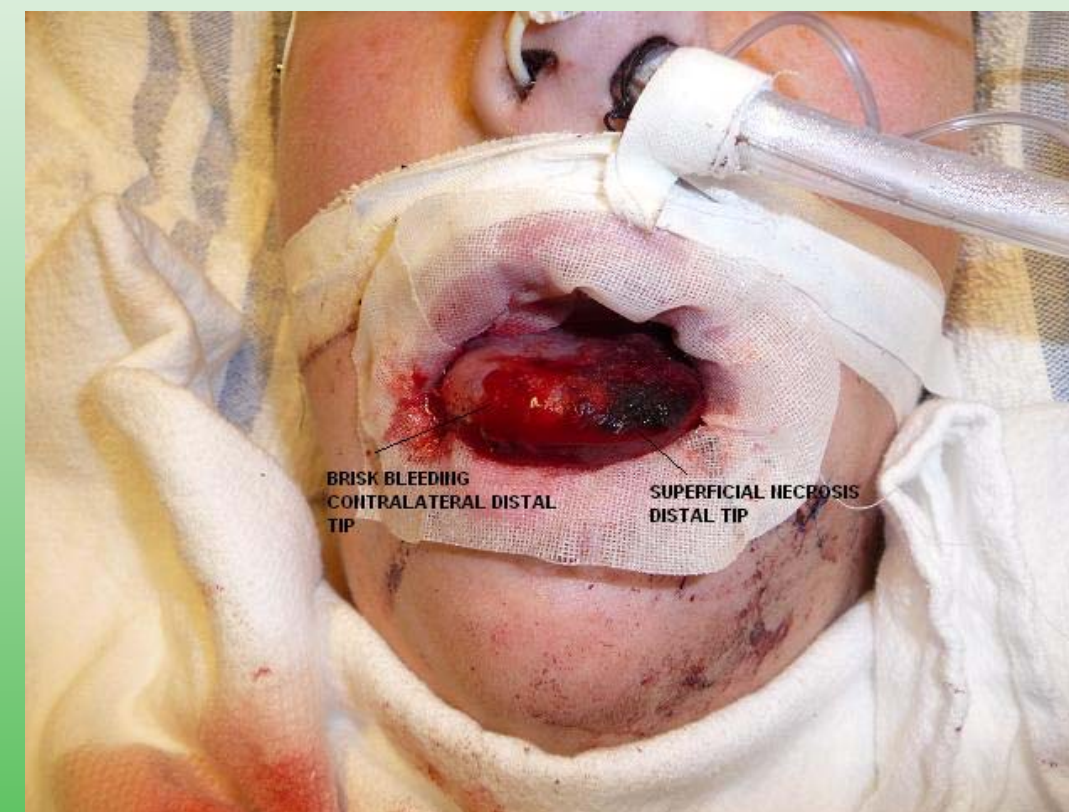

Figure 4: Demarcation of necrosis and distal brisk bleeding

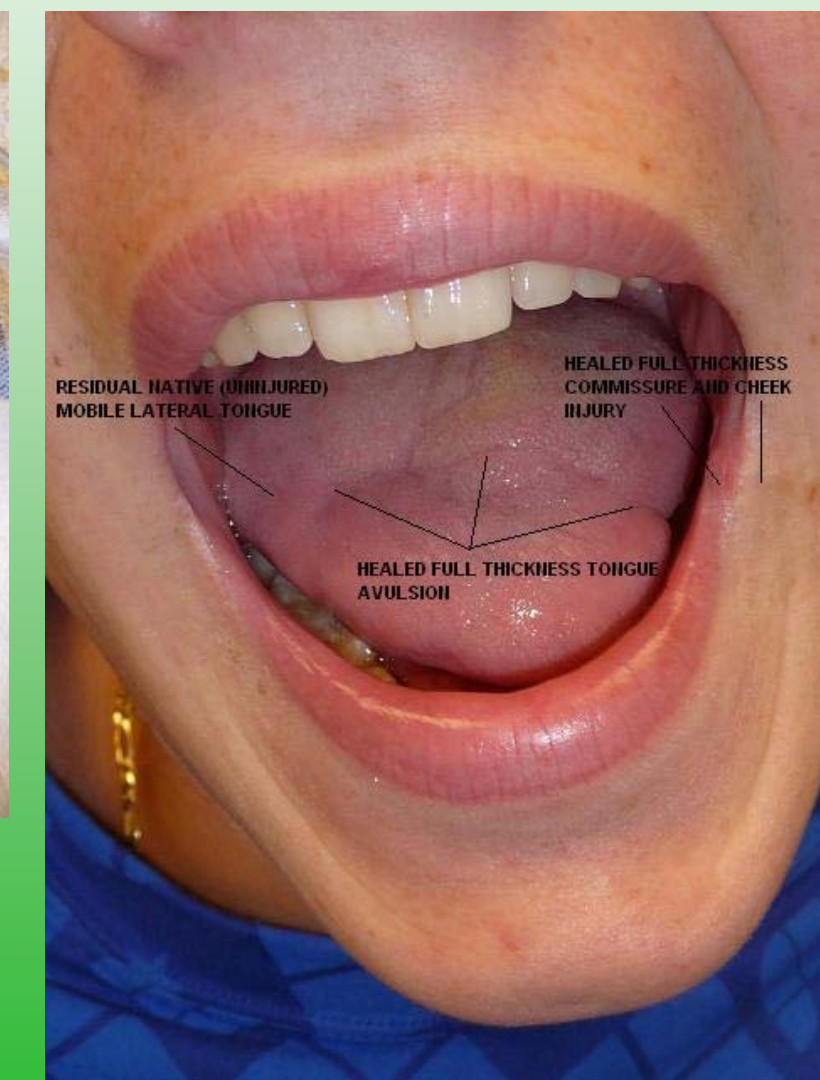

Figure 5: Final result

## DISCUSSION

From its earliest beginnings dated to 200BC by Nicander of Colophon, hirudotherapy has been a long-established medical treatment. In cases of tissue-threatening venous congestion, where outflow obstruction leads to microcirculatory collapse and tissue ischemia, hirudotherapy can effectively reverse venous stasis while the microcirculation reestablishes itself. Derganc has been widely credited for the original use of hirudotherapy in flap salvage. Hirudin, among other anticoagulative substrates found in leech saliva, inhibits platelet aggregation and increases tissue permeability; both necessary therapeutic effects to counteract erythrocyte extravasation and the pro-coagulative micro-environment seen with venous congestion. Hirudotherapy is not without the risk of complications however, the most substantive of which being infection and blood loss. Standard protocols for coverage of common bacterial pathogens found in leech saliva include the use of quinolones, aminoglycosides, third-generation cephalosporins or sulfa drugs. Daily hemograms and coagulation studies are also indicated to assure blood loss is well controlled.

## CONCLUSIONS

We present the first reported case in the English medical literature of successful salvage of a near-total mobile tongue amputation with hirudotherapy. Hirudotherapy is a viable option for tissue threatening venous congestion and should be in the surgeon's armamentarium in cases of traumatic tissue avulsion.

## REFERENCES

- Frodel, J.L., Barth, P., Wagner, J. Salvage of Partial Facial Soft Tissue Avulsion with Medicinal Leeches. *Otolaryngology-Head and Neck Surgery*. 131(6): 934-9, December 2004.
- Abdelgabar, A.M., Bhowmick, B.K. The Return of the Leech. *International Journal of Clinical Practice*. 57(2): 103-5, March 2003.
- Chepeha, D.B., Nussenbaum, B., Bradford, C.R., Teknos, T.N. Leech Therapy for Patients with Surgically Unsalvageable Venous Obstruction after Revascularized Free Tissue Transfer. *Archives of Otolaryngology-Head and Neck Surgery*, 128(8): 960-5, August 2002.
- Connor, N.P., Conforti, M.L., Heisey, D.M., Vanderby, R., Kunz, D., Hartig, G.K. Augmented Blood Removal after Medicinal Leech Feeding in Congested Tissue Flaps. *Journal of Rehabilitation Research and Development*. 39(4): 505-12, July-August 2002.
- Conforti, M.L., Connor, N.P., Heisey, D.M., Hartig, G.K. Evaluation of Performance Characteristics of the Medicinal Leech (*Hirudo Medicinalis*) for the Treatment of Venous Congestion. *Plastic and Reconstructive Surgery*. 109(1): 228-35, January 2002
- Utley, D.S., Koch, R.J., Goode, R.J. The Failing Flap in Facial Plastic and Reconstructive Surgery: Role of the Medicinal Leech. *Laryngoscope*. 108(8): 1129-35, August 1998.
- Derganc, M., Zdravic, F. Venous Congestion of Flaps Treated by Application of Leeches. *British Journal of Plastic Surgery*. 13:187-92, July 1960.